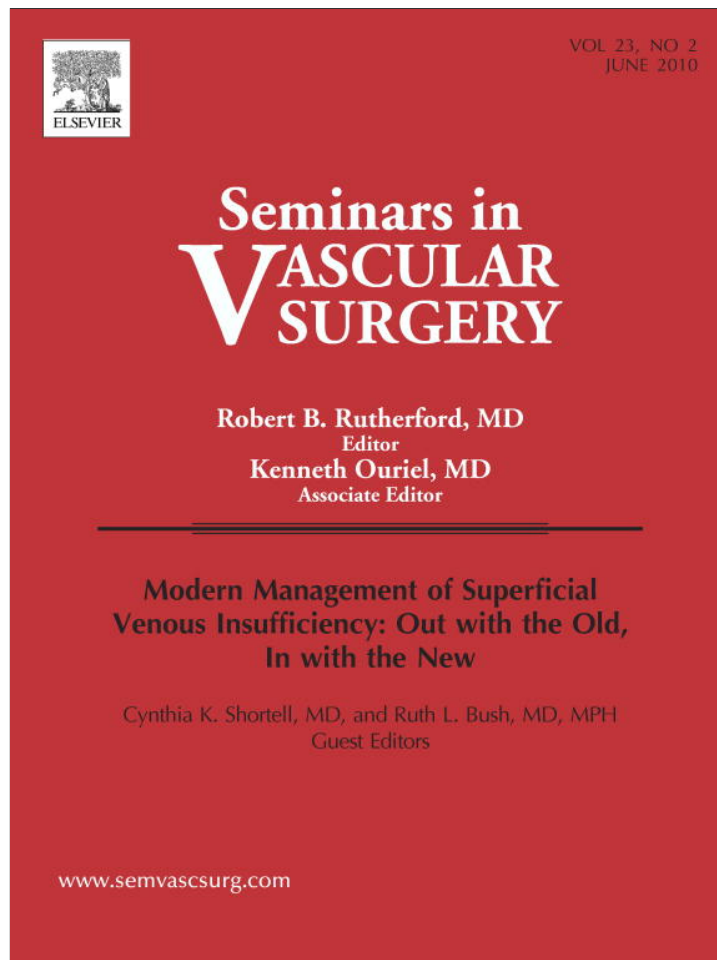


Provided for non-commercial research and education use.  
Not for reproduction, distribution or commercial use.



This article appeared in a journal published by Elsevier. The attached copy is furnished to the author for internal non-commercial research and education use, including for instruction at the authors institution and sharing with colleagues.

Other uses, including reproduction and distribution, or selling or licensing copies, or posting to personal, institutional or third party websites are prohibited.

In most cases authors are permitted to post their version of the article (e.g. in Word or Tex form) to their personal website or institutional repository. Authors requiring further information regarding Elsevier's archiving and manuscript policies are encouraged to visit:

<http://www.elsevier.com/copyright>



# CHIVA

Eric Mowatt-Larssen, MD, and Cynthia Shortell, MD

**Based on a theoretical hemodynamic model, CHIVA (conservative hemodynamic cure for venous insufficiency) is an ultrasound-guided, minimally invasive surgical strategy performed under local anesthesia for the treatment of patients with varicose vein disease. After careful duplex mapping, the surgeon performs flush ligation procedures at the proximal origin of key points of reflux while meticulously maintaining superficial venous drainage to prevent varicosity recurrence. The saphenous veins are preserved. The strategy has been shown in studies to be safe and effective.**

**Semin Vasc Surg 23:118-122 © 2010 Elsevier Inc. All rights reserved.**

*Things should be made as simple as possible, but not simpler.*  
—Albert Einstein<sup>1</sup>

BASED ON A theoretical hemodynamic model, CHIVA is a minimally invasive, ultrasound-guided surgical strategy performed under local anesthesia for the treatment of varicose veins. The principles of CHIVA were first articulated by Claude Franceschi, an early pioneer in ultrasound and Doppler technology.<sup>2</sup> The name CHIVA is an acronym for *conservatrice et hemodynamique de l'insuffisance veineuse en ambulatoire*, or, in English, conservative hemodynamic cure for venous insufficiency. CHIVA is one specific type of conservative surgery. It is a different strategy than other conservative techniques such as pure saphenofemoral ligation, or saphenofemoral ligation combined with phlebectomies. CHIVA is now used in around 50% of varicose vein operation in Spain, and is also performed in many other countries.<sup>3</sup>

CHIVA is built on two important principles, which are different from traditional approaches. First, the surgeon interrupts reflux at its proximal origin by flush ligation and does not eliminate the entire region of reflux. In this way, the surgeon interrupts a recirculation pressure loop producing the ambulatory venous hypertension critical to the development of varicose vein symptoms. The goal in CHIVA is thus different from the conventional surgical goal of elimination of all or most reflux.<sup>4</sup>

Equally important, refluxing vessels now interrupted by flush ligation will drain into deep veins through preoperatively identified "reentry" perforator veins. The second important principle is that the proper drainage of the ligated but still refluxing vein will prevent recurrent varicosities common in traditional stripping and phlebectomy. The saphenous vein, in particular, is preserved to allow proper drainage. It is also available as a potential future bypass graft.

nous vein, in particular, is preserved to allow proper drainage. It is also available as a potential future bypass graft.

## Hemodynamic Shunts

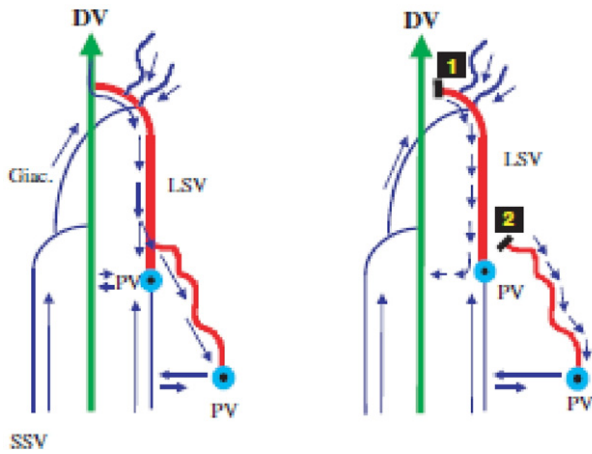
In CHIVA, the surgeon identifies shunts, or abnormal flow between vein compartments (such as between deep and superficial, or saphenous and tributary) with combined reflux and reentry resulting in a blood flow loop. These loops can be diagnosed by careful ultrasound mapping. Armed with this information, the physician can interrupt the blood column at the origin of reflux by flush ligation, and preserve reentry points to decrease varicose recurrence.<sup>2</sup> Around 30% of patients have shunt type 1 (Fig 1).<sup>5</sup> The reflux in this shunt begins at the deep-saphenous junction, with reentry through a perforator vein from saphenous back to deep vein. A tributary vein can often be refluxing as well, but a reentry perforator distal to the tributary origin located on the saphenous rather than only the tributary vein should be detected on ultrasound. Characteristically the saphenous diameter decreases below the origin of the refluxing tributary, although the saphenous reflux persists until the reentry point. Patients with shunt type 1 should be treated with the CHIVA 1 procedure (Fig 1): flush ligation at the deep-saphenous junction and flush ligation at the junction between saphenous and refluxing tributary.

Approximately 60% of patients have shunt type 3 (Fig 2).<sup>5</sup> The reflux in this shunt type also begins at the deep-saphenous junction, and progresses to a tributary, but reenters to the deep system via a perforator on the tributary vein, rather than the saphenous vein. Occasionally, the reentry point can be on the saphenous vein, but only if the refluxing tributary connects from saphenous to saphenous vein (eg, the intersaphenous [Giacomini] vein). In this case, the ultrasonographer should find lack of reflux distal to the origin of the refluxing

---

Division of Vascular Surgery, Duke University Medical Center, Durham, NC. Address reprint requests to Eric Mowatt-Larssen, 3475 Erwin Road, Durham, NC 27705. E-mail: eric.mowatt-larssen@duke.edu

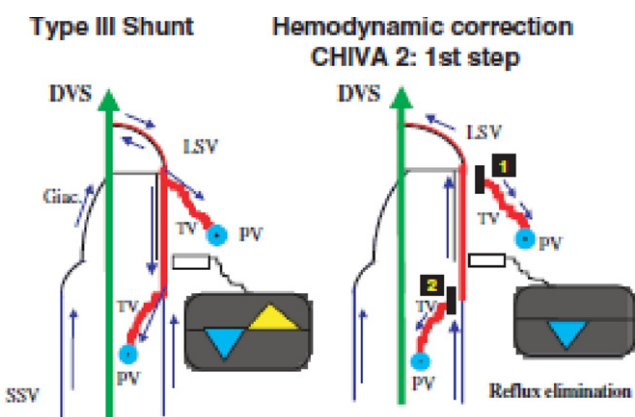
**Type I Shunt Hemodynamic correction CHIVA 1**



**Figure 1** Type 1 shunt. Left: In this common type 1 shunt example, the blood moves from deep veins (DV) into the great saphenous vein (LSV) and reenters the deep veins through a reentry perforator (PV) on the great saphenous vein. There is also a refluxing tributary vein. Right: Type 1 shunt is corrected by disconnection of the great saphenous vein at the saphenofemoral junction and disconnection of the refluxing tributary vein at the saphenous-tributary junction. Giac., intersaphenous (Giacomini) vein; SSV, small saphenous vein. Reprinted from Zamboni P, Cisno C, Marchetti F, et al: Minimally invasive surgical management of primary venous ulcers vs. compression treatment: A randomized clinical trial. *Eur J Vasc Endovasc Surg* 25:313-318, 2003, with permission.

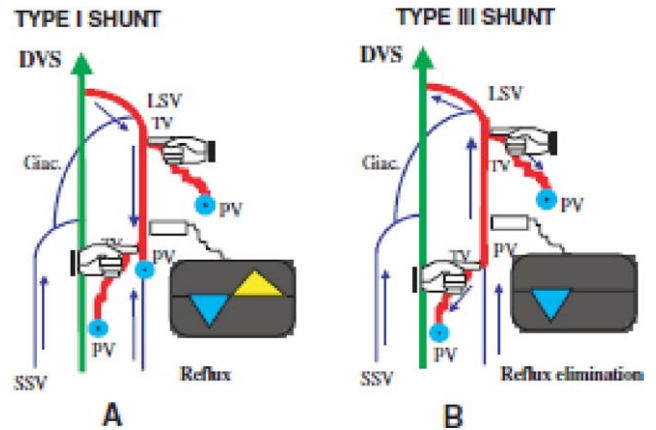
tributary and return of segmental saphenous reflux closer to a the reentry perforator.

The Reflux Elimination Test differentiates between shunt type 1 with refluxing tributary and shunt type 3, as shown in



**Figure 2** Type 3 Shunt. Left: In this common type 3 shunt example, the blood flows from the deep veins (DV) into the great saphenous vein (LSV) and reenters the deep veins through a reentry perforators on the refluxing tributary veins (TV). Right: The first step of the correction is disconnection of the saphenous-tributary junctions. Giac., intersaphenous (Giacomini) vein; PV, reentry perforator vein; SSV, small saphenous vein; TV, refluxing tributary vein. Reprinted from Zamboni P, Cisno C, Marchetti F, et al: Minimally invasive surgical management of primary venous ulcers vs. compression treatment: A randomized clinical trial. *Eur J Vasc Endovasc Surg* 25:313-318, 2003, with permission.

**SHUNT IDENTIFICATION**

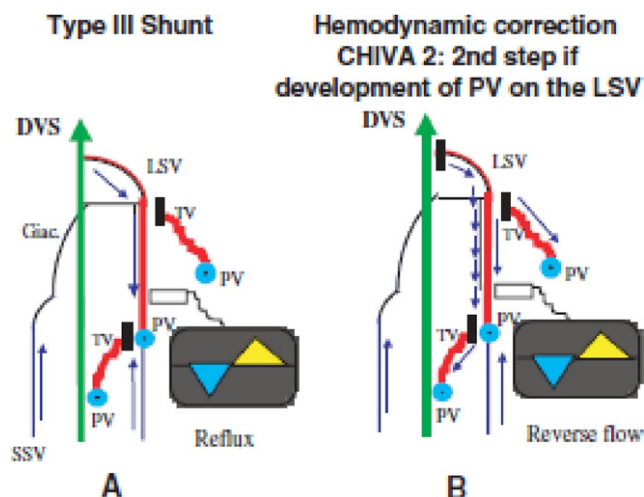


**Figure 3** Reflux elimination test: Finger pressure is applied to each proximal refluxing tributary vein (TV) and the extremity is squeezed while the great saphenous vein (LSV) is monitored for reflux. (A) If the reflux persists at any tributary vein despite the finger pressure, the patient has a Type 1 shunt, with reentry perforator (PV) on the great saphenous vein. (B) If the reflux is eliminated at every refluxing tributary vein, the patient has a type 3 shunt, with reentry on the refluxing tributary veins. DV, deep veins; Giac., intersaphenous (Giacomini) vein; SSV, small saphenous vein. Reprinted from Zamboni P, Cisno C, Marchetti F, et al: Minimally invasive surgical management of primary venous ulcers vs. compression treatment: A randomized clinical trial. *Eur J Vasc Endovasc Surg* 25:313-318, 2003, with permission.

Figure 3.<sup>6</sup> The ultrasonographer places a finger at the origin of each refluxing tributary and checks for the absence of reflux at the deep-saphenous junction. If the junctional reflux disappears at all the refluxing tributaries, the patient has a type 3 shunt.

Shunt type 3 is treated using the CHIVA 2 procedure. In Step 1 (Fig 2), the refluxing tributary is disconnected from the saphenous vein, flush ligation is performed, followed by phlebectomy of 2 to 4 cm of the proximal tributary. Disconnecting the saphenous from the deep vein concomitantly does not provide for proper saphenous drainage and increases the risk of superficial thrombophlebitis.<sup>7</sup> Some patients will develop a saphenous reentry perforator detected at follow-up. These patients now have developed a type 1 shunt. These patients should undergo step 2 (Fig 4), or disconnection of saphenous from the deep system at the deep saphenous junction.

Patients requiring CHIVA 2, step 2 may be predicted by the presence of an incompetent terminal valve on the great saphenous vein. Cappelli et al point out the importance of the hemodynamics of the saphenofemoral junction.<sup>8</sup> Zamboni describes the process to test the terminal valve with Doppler sample placed at the common femoral vein instead of the saphenous arch.<sup>9</sup> The terminal valve is competent if there is <0.5 seconds of reflux with the Valsalva maneuver, manual muscle compression, or voluntary muscle contraction. Patients with a competent terminal valve rarely need step 2.



**Figure 4** CHIVA (conservative hemodynamic cure for venous insufficiency) 2, step 2. (A) After CHIVA 2, step 1, some patients will develop great saphenous vein (LSV) reflux with reentry perforator (PV) on the great saphenous vein. (B) In CHIVA 2, step 2, the great saphenous vein is disconnected at the saphenofemoral junction. DV, deep veins; Giac., intersaphenous (Giacomini) vein; SSV, small saphenous vein. Reprinted from Zamboni P, Cisno C, Marchetti F, et al: Minimally invasive surgical management of primary venous ulcers vs. compression treatment: A randomized clinical trial. *Eur J Vasc Endovasc Surg* 25:313-318, 2003, with permission.

Approximately 90% of patients with varicose vein disease have shunts 1 or 3. Because these shunts are the most common and most of the research on CHIVA concerns these shunts, this article will discuss only these specific shunts. The interested reader is referred to Franceschi<sup>5</sup> for a more detailed discussion.

## Efficacy and Safety

In 2008, Carandina et al from Ferrara, Italy reported the results of a randomized clinical trial comparing the CHIVA 1 technique to GSV stripping in 150 patients with a type 1 shunt.<sup>10</sup> With mean follow-up of 10 years, patients who received CHIVA 1 showed a 17% absolute decrease in varicose vein recurrence compared to patients who received stripping (18% for CHIVA v 35% for stripping). Recurrence was defined as ultrasound-determined reflux or any varicosities >5 mm in diameter in the treated extremity. Patients also had less recurrence after CHIVA when defined by objective Hobbs score<sup>11</sup> from three independent, blinded assessors. Interestingly, patient satisfaction, measured by quality-of-life questionnaire completed by patients with possible responses ranging from no inconvenience to increased inconvenience, was similar in the two techniques. In a separate prospective case series in 1998 from Ferrara, Zamboni et al showed that patients who underwent the CHIVA 1 procedure had a significant decrease in foot ambulatory vein pressure at 6 months.<sup>12</sup>

In 2003, Escribano et al reported the results of a prospective study of CHIVA treatment of type 3 shunt.<sup>13</sup> They performed CHIVA 2, step 1 and had 3-year follow-up. Using the

Hobbs classification,<sup>11</sup> the CHIVA strategy achieved cure in 90% (52/58) of patients, and improvement in 10% (6/58), with no failures. However, 92% of patients (53/58) required CHIVA 2, step 2, or interruption of the saphenofemoral junction, during follow-up.

In a 2001 prospective case series, Zamboni et al reported on 40 patients with type 3 shunt at 6-month follow-up corrected by CHIVA 1, step 1 only.<sup>6</sup> Eighty-eight percent (35/40) of patients were free of varicosities and 85% (34/40) were free of saphenous reflux by ultrasound. Air plethysmographic parameters, including venous volume, venous filling index, and residual volume fraction, improved significantly. Venous ejection fraction, however, did not improve significantly. In this group, only 15% (6/40) required CHIVA 2, step 2, in contrast to the 92% in the Barcelona study. However, the Ferrara group applies more stringent requirements than the Barcelona group for defining a type 3 versus type 1 shunt. The Ferrara group tests each visible saphenous perforator, while pressing on the origin of refluxing tributaries. Any reflux designates that extremity a type 1 shunt, and the patient undergoes CHIVA 1, with concomitant flush ligation of the saphenofemoral junction and origin of refluxing tributary veins.<sup>14</sup>

In 2001, Maeso et al<sup>15</sup> compared CHIVA to stripping in 175 patients at 3-year follow-up in a prospective, nonrandomized case review study. CHIVA patients had a better outcome in measures including presence of varicosities (1.1% v 15%), postoperative symptoms (1.1% v 21%), saphenous nerve injury (1.1% v 19%), and patient dissatisfaction (3.3% v 16%).

In a 2003 randomized clinical trial, Zamboni et al showed CHIVA to be more effective than compression therapy alone in 47 limbs eligible for treatment for venous leg ulcers and followed for 3 years.<sup>16</sup> The CHIVA group had faster healing times (100% in 31 days for CHIVA; 96% in 63 days for compression only) and ulcer recurrence (9% in CHIVA v 38% in compression only).

Cappelli et al noted a 25% (72/289) rate of saphenous thrombophlebitis in a 2000 CHIVA retrospective case series.<sup>7</sup> Zamboni et al showed this complication could be prevented by staging the CHIVA 2 treatment of type 3 shunts to preserve reentry flow as discussed earlier.<sup>12</sup> Deep vein thrombosis has not been reported in the major CHIVA studies in English. CHIVA may have a reduced rate of saphenous nerve injury and work disability compared to conventional surgical stripping.<sup>7</sup>

## Training and Practical Considerations

Successful CHIVA requires significant surgeon training and experience as well as a complete understanding of the underlying venous hemodynamic principles. An incomplete understanding of CHIVA may produce worse results than conventional therapies. The interested physician is directed to courses run by Drs. Claude Franceschi and Roberto Delfrate

in Cremona, Italy, for training, and the recent 2009 text by Drs. Franceschi and Paolo Zamboni.<sup>17</sup>

CHIVA also requires accurate ultrasound mapping and physician presence during the ultrasound evaluation, as the procedures are ultrasound-guided. The technique, therefore, requires a significant time commitment on the part of the physician. The surgeon also must have meticulous technique in flush ligation to prevent thrombosis. Basic superficial CHIVA techniques are not effective in patients with deep vein reflux, but the same hemodynamic principles can be applied to interrupt deep recirculation pressure loops using the CHIVP method (deep CHIVA). Patient expectations must be managed to allow patience for veins distal to the treated areas to improve instead of the more immediate results seen with elimination or ablation of all axial venous reflux.

## Endovascular Implications

In a recent 2009 meta-analysis, van den Bos et al. found the new endovascular techniques endovenous laser ablation (EVLA), radiofrequency ablation (RFA), and ultrasound-guided foam sclerotherapy, as least as effective as stripping in eliminating saphenous reflux.<sup>18</sup> Pooled ultrasound-determined saphenous vein ablation rates at 3 years were: EVLA, 94%; RFA, 84%; ultrasound-guided foam sclerotherapy, 77%; and stripping, 78%. Saphenous vein reflux recurrence rates were: EVLA 6%; RFA, 16%; ultrasound-guided foam sclerotherapy, 23%; and stripping, 22%. These recurrence rates cannot be directly compared to the 18% at 10 years in the Carandina et al study<sup>10</sup> because the patient groups vary; the CHIVA study had longer 10-year follow-up; and because recurrence in the CHIVA study is more broadly defined as any varicosity >5 mm in diameter as well as any ultrasound recurrence, not just reflux in the saphenous vein. CHIVA, however, does appear competitive. In a 2005 multicenter prospective case series looking at RFA with 5-year follow-up, Merchant and Pichot found a 27% (32/117) rate of varicose vein recurrence, a 16.2% (19/117) rate of saphenous vein reflux recurrence, and a 12.8% (15/117) rate failure to completely obstruct the treated vein.<sup>19</sup> In a 2003 prospective case series looking at EVLA with 2-year follow-up, Min et al found a saphenous vein reflux recurrence rate of 6.6% (8/121).<sup>20</sup>

The CHIVA strategy can be applied using endovascular therapies. Such an approach would combine the hemodynamic and venous drainage preservation benefits from CHIVA with the minimally invasive nature of endovascular techniques. The surgical flush ligations of the traditional CHIVA technique could be replaced by short-segment ablation using laser fiber, radiofrequency catheter, or sclero-foam, while the hemodynamic principles of CHIVA could be used to select targets. The minimum segment treatable with persistent success with heat or chemical ablation is not known, but the success of these techniques in treating incompetent perforator veins suggest this procedure can be successful. The CHIVA surgeon could, for example, treat a 4- to 5-cm segment of saphenous or tributary vein, instead of the 2- to 4-cm phlebectomy performed by the CHIVA surgeon.

## To Model or Not to Model—That is the Question

The CHIVA model itself also needs to be taken seriously. As with any model, CHIVA simplifies a complex reality. Simplification is a good thing as long as the simplification does not adversely affect patient outcomes. Isaac Newton had a superb model to explain gravity, and it successfully predicted the vast majority of natural observations, such as planetary orbits. Albert Einstein improved on the model, explaining additional observations, such as discrepancies in Mercury's orbit. Newton's model is still useful in most situations even today. As Einstein noted, "Things should be made as simple as possible, but not simpler."<sup>1</sup>

Lurie notes that we have inconsistencies in our current thinking about varicose vein disease.<sup>21</sup> In fact, our current thinking is based on eliminating reflux because it is abnormal. This empirical observation is not a model. Endovascular options use the same thinking, replacing surgical elimination with ablation. Yet this strategy is plagued by disease recurrence and a mild to moderate degree of early postoperative morbidity. The conventional strategy has room for improvement.

## Conclusions

CHIVA is a reasonable option to treat patients with varicose veins or venous insufficiency. CHIVA surgeons have shown low rates of ultrasound-determined reflux, low rates of physical examination-determined varicosity recurrence, improved postsurgical venous physiologic parameters, and good patient satisfaction. To achieve these results, the CHIVA surgeon needs a thorough understanding of venous hemodynamics and expertise in ultrasound. The impressive data from Ferrara, Italy, however, needs to be verified at other centers.

CHIVA has several advantages over traditional stripping. Venous drainage is almost completely preserved. The strategy may produce fewer varicosity recurrences. The great saphenous vein is preserved as a potential arterial bypass conduit. Patients may have a reduced rate of saphenous nerve injury and work disability.

A robust theoretical model is critical to the advancement of phlebology in the modern age. CHIVA generates a testable surgical strategy that can verify the underlying model and allow comparison by randomized clinical trials to the many alternative treatments available to help patients disabled by varicose veins or venous insufficiency.

## References

1. Einstein A: Albert Einstein. Available at: [http://simple.wikiquote.org/wiki/Albert\\_Einstein](http://simple.wikiquote.org/wiki/Albert_Einstein). Accessed August 19, 2009
2. Franceschi C: Theory and Practice of the Conservative Haemodynamic Cure of Incompetent and Varicose Veins in Ambulatory Patients, translated by Evans J. Precy-sous-Thil. 1988
3. Mendoza E: CHIVA 1988-2008. Review of studies on the CHIVA method and its development in different countries. *Gefasschirurgie* 13:249-256, 2008

4. Bergan J: Inversion stripping of the saphenous vein, in Bergan JJ (ed): *The Vein Book*. New York, Elsevier, 2007, p 234
5. Franceschi C: Shunt's classification, in Franceschi C, Zamboni P (eds): *Principles of Venous Hemodynamics*. New York, Nova Biomedical Books, 2009, pp 55-64
6. Zamboni P, Cisno C, Marchetti F, Quaglio D, Mazza P, Liboni A: Reflux elimination without any ablation or disconnection of the saphenous vein. A haemodynamic model for surgery. *Eur J Vasc Endovasc Surg* 21:361-369, 2001
7. Cappelli M, Lova RM, Ermini S, et al: Ambulatory conservative hemodynamic management of varicose veins: Critical analysis of results at 3 years. *Ann Vasc Surg* 14:376-384, 2000
8. Cappelli M, Lova RM, Ermini S, Giangrandi I, Gianelli F, Zamboni P: Hemodynamics of the sapheno-femoral complex: An operational diagnosis of proximal femoral valve function. *Int Angiol* 25:356-360, 2006
9. Zamboni P: From the map to CHIVA Procedure, in Franceschi C, Zamboni P (eds): *Principles of Venous Hemodynamics*. New York, Nova Biomedical Books, 2009, pp 125, 129
10. Carandina S, Mari C, De Palma M, et al: Varicose vein stripping vs haemodynamic correction (CHIVA): A long term randomised trial. *Eur J Vasc Endovasc Surg* 35:230-237, 2008
11. Hobbs JT: Surgery and sclerotherapy in the treatment of varicose veins. *Arch Surg* 190:793-796, 1974
12. Zamboni P, Marcellino MG, Cappelli M, et al: Saphenous vein sparing surgery: Principles, techniques and results. *J Cardiovasc Surg* 39:151-162, 1998
13. Escribano JM, Juan J, Bofill R, Maeso J, Rodriguez-Mori A, Matas M: Durability of reflux-elimination by a minimal invasive CHIVA procedure on patients with varicose veins. A 3-year prospective case study. *Eur J Vasc Endovasc Surg* 25:159-163, 2003
14. Zamboni P, Escribano JM: Regarding 'reflux elimination without any ablation or disconnection of the saphenous vein. A haemodynamic model for surgery and 'durability of reflux-elimination by a minimal invasive CHIVA procedure on patients with varicose veins. a 3-year prospective case study.' *Eur J Vasc Endovasc Surg* 28:567-568, 2004
15. Maeso J, Juan JJ, Escribano JM, et al: Comparison of clinical outcome of stripping and CHIVA for treatment of varicose veins in the lower extremities. *Ann Vasc Surg* 15:661-665, 2001
16. Zamboni P, Cisno C, Marchetti F, et al: Minimally invasive surgical management of primary venous ulcers vs. compression treatment: A randomized clinical trial. *Eur J Vasc Endovasc Surg* 25:313-318, 2003
17. Franceschi C, Zamboni P: *Principles of Venous Hemodynamics*. New York, Nova Biomedical Books, 2009
18. van den Bos R, Arends L, Kocharaert M, Neumann M, Nijsten T: Endovenous therapies of lower extremity varicosities: A meta-analysis. *J Vasc Surg* 49:230-239, 2009
19. Merchant RF, Pichot O, Closure Study Group: Long-term outcomes of endovenous radiofrequency obliteration of saphenous reflux as a treatment for superficial venous insufficiency. *J Vasc Surg* 42:502-509, 2005
20. Min RJ, Khilnani N, Zimmet SE: Endovenous laser treatment of saphenous vein reflux: Long-term results. *J Vasc Interv Radiol* 14:991-996, 2003
21. Lurie F: Venous haemodynamics: What we know and don't know. *Phlebology* 24:3-7, 2009